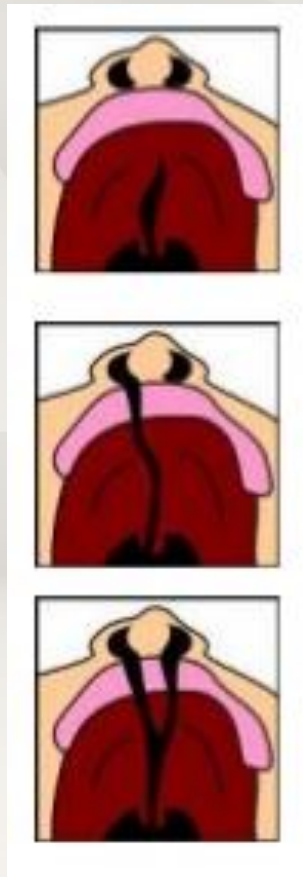
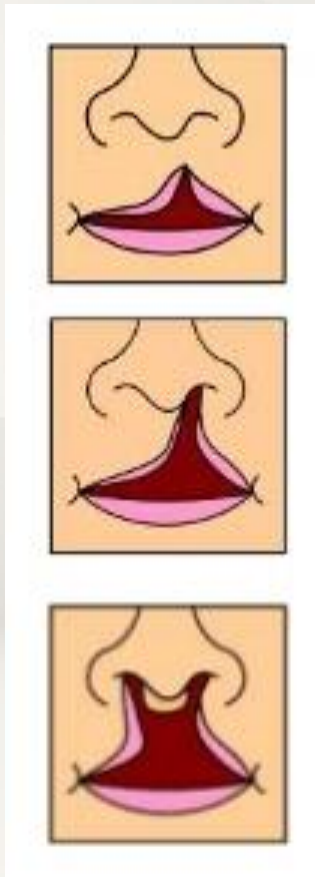


Lamphun Hospital Cleft Care



ทพญ. อนรรดี ศิริพานิชกร
ทพญ. ปิยะวัลย์ หอภัทรพุดธิ
ทันตกรรมสำหรับเด็ก
โรงพยาบาลลำพูน

Lamphun Hospital Cleft Team

- Pediatrician
- ENT
- Plastic surgeon
- Nurse
- Maxillofacial surgeon
- Orthodontist
- Pedodontist
- Prosthodontist
- Speech
- Case manager

Interdisciplinary team

Lamphun Hospital
Cleft Management
Guideline

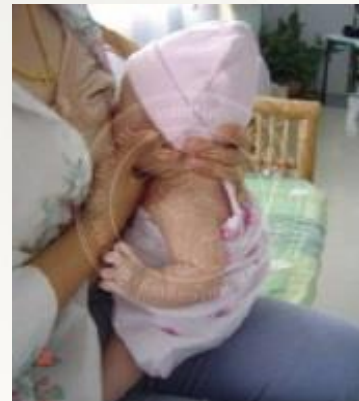
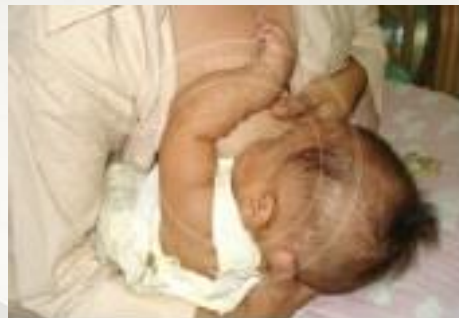
Lamphun Hospital Cleft Management Guideline

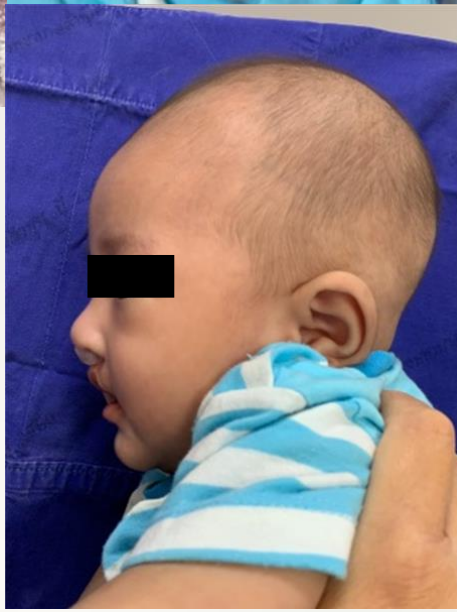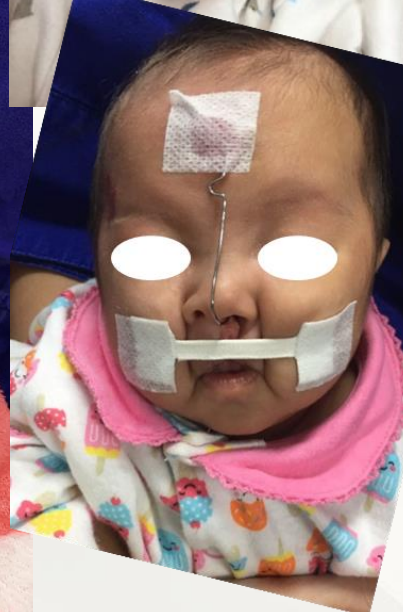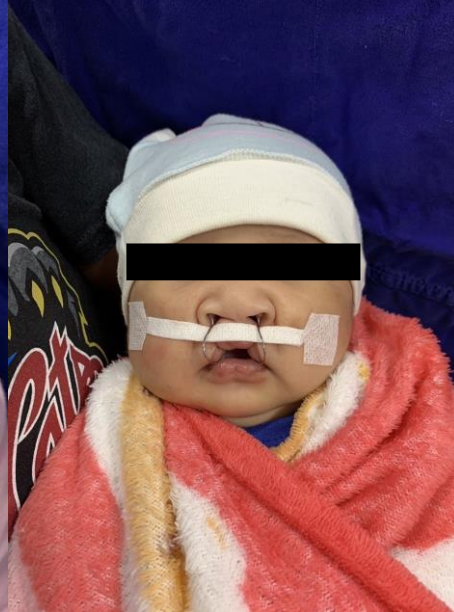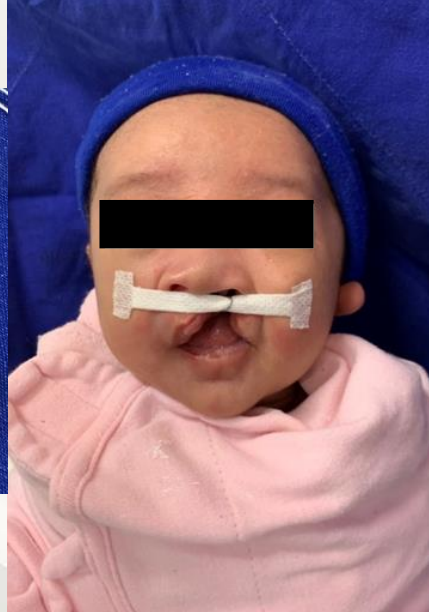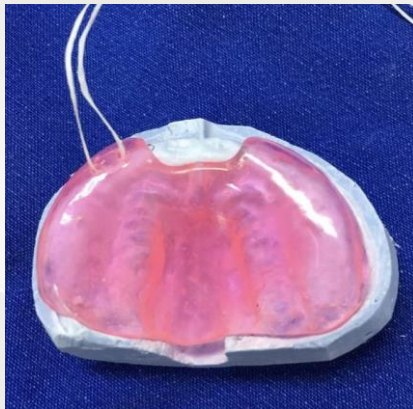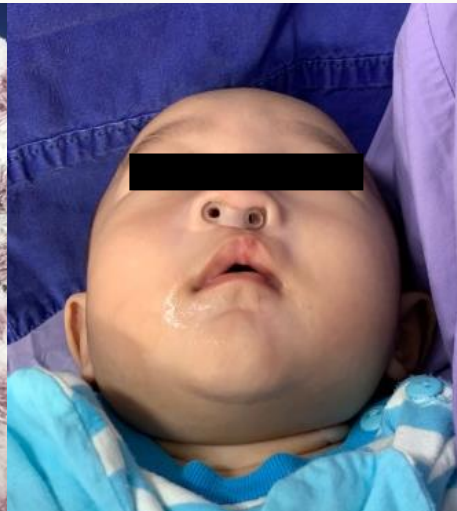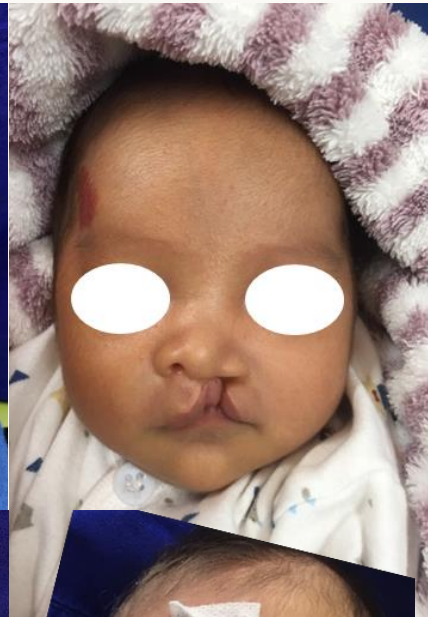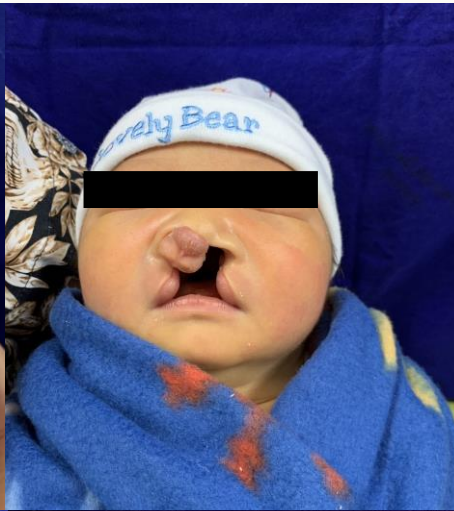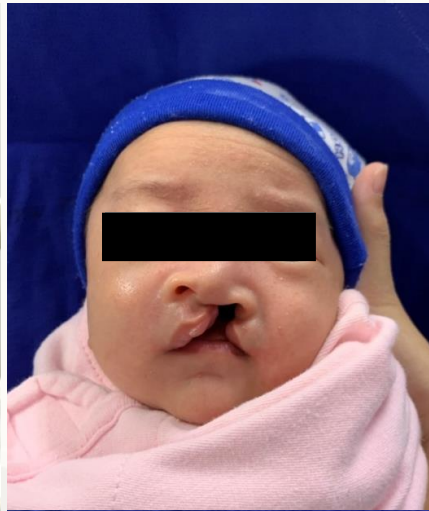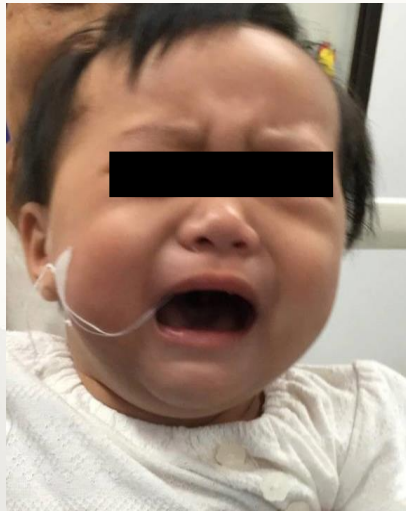| Age | Orthodontist | Pedodontist | Plastic surgeon/ Maxillofacial surgeon | General dentist | Prosthodontist |
|----------------|--|--|--|--------------------|---|
| 0-3 mo | - Obturator , NAM - Consult surgeon | Oral hygiene instruction | Counseling For surgery | | |
| 3-6 mo | - Obturator , NAM - Nasal stent (after primary cheiloplasty 24 hrs/day for 6 months, followed by 6-12 hrs/day) | Oral hygiene instruction | Cheiloplasty | | |
| 6 mo - 1 yr | - Obturator - Continued nasal stent | Oral hygiene instruction | | | |
| 1-1.5 yr | | Dental care | Palatoplasty | | |
| 1.5 – 7 yr | Observed growth and occlusion | - Dental care - Observed dental development | | | |
| 7-9 yr | Interceptive Treatment for alveolar bone graft (arch expansion) | Dental care | | Dental care | |
| 9-12 yr | - Interceptive Treatment for crossbite correction or growth modification - Nasal stent (after 2 nd cheiloplasty 24 hrs/day for 12 months , followed by 6-12 hrs/day) | Dental care | Alveolar bone grafting ± 2 nd lip and nose revision | Dental care | |
| 12-18 yr | Orthodontic treatment | | | Dental care | Prosthodontic Treatment (when indicated) |
| > 18 yr | Orthodontic treatment for orthognathic surgery | | Orthognathic surgery | Dental care | |

Breast feeding

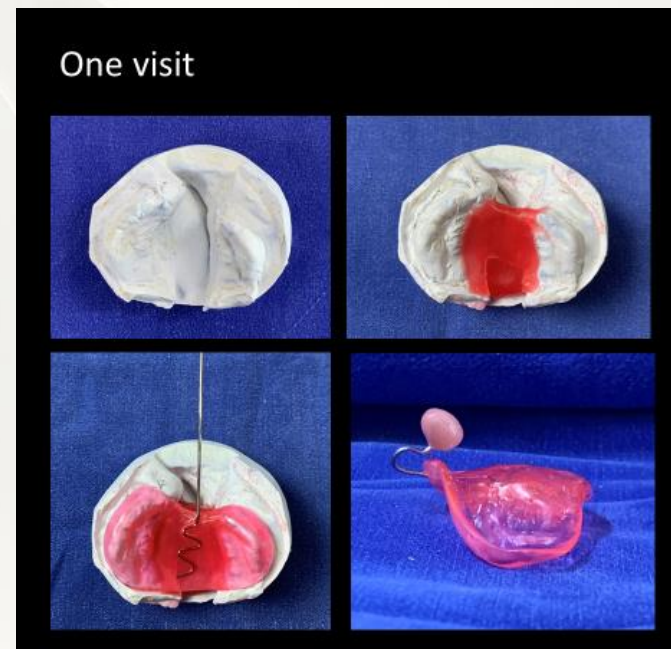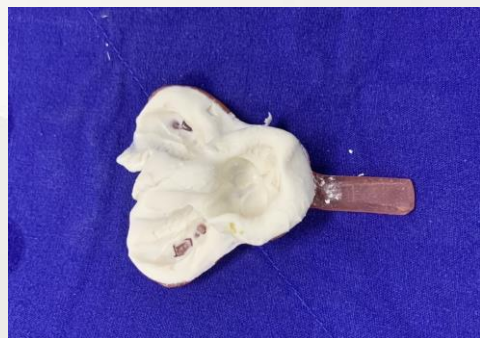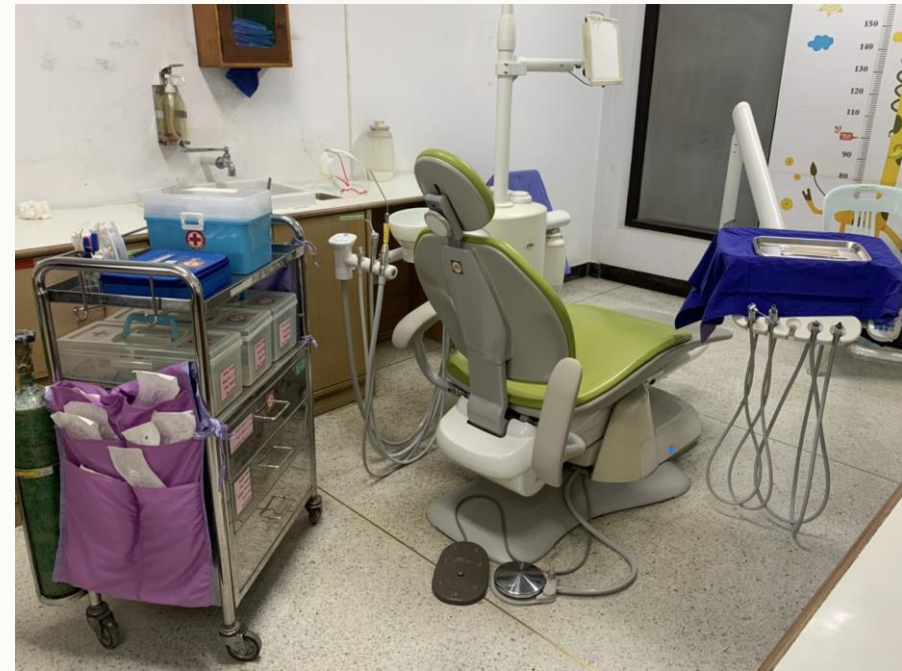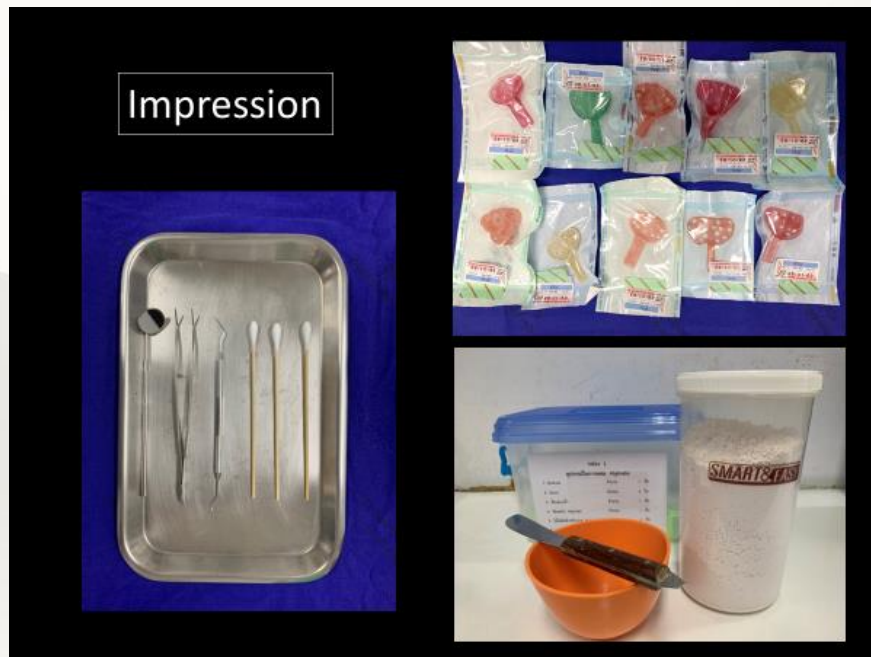Breast feeding



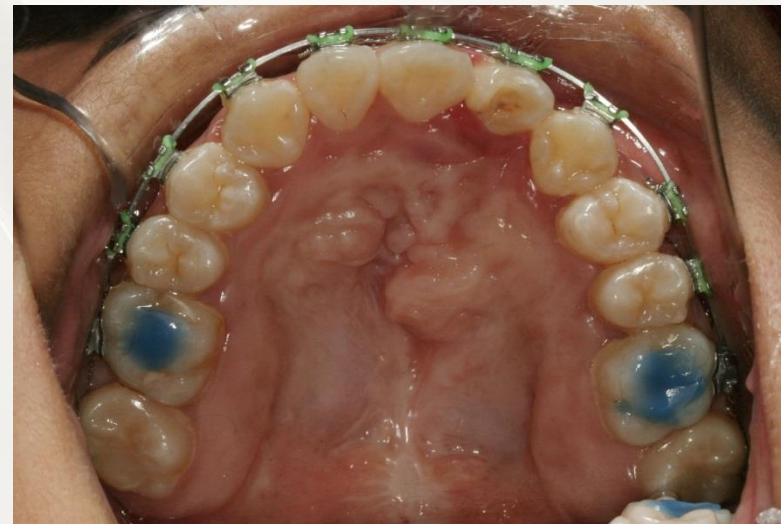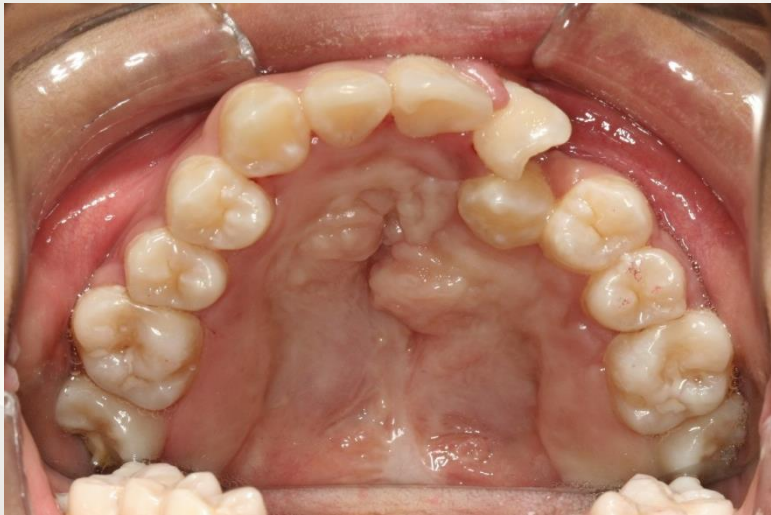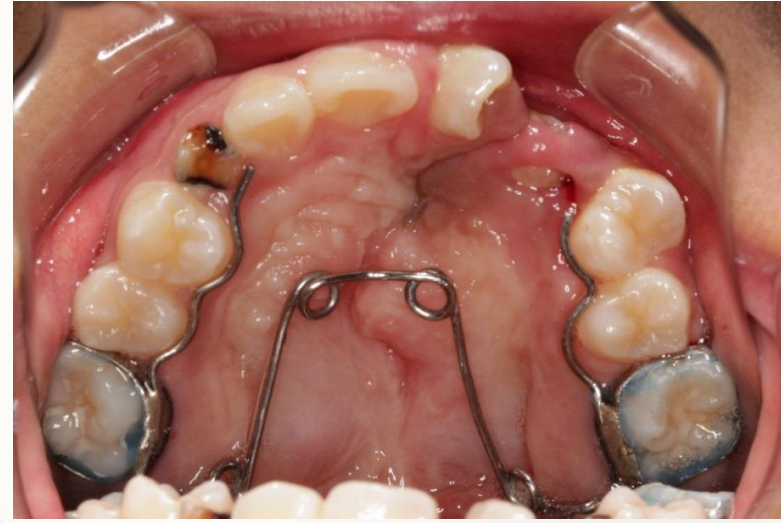
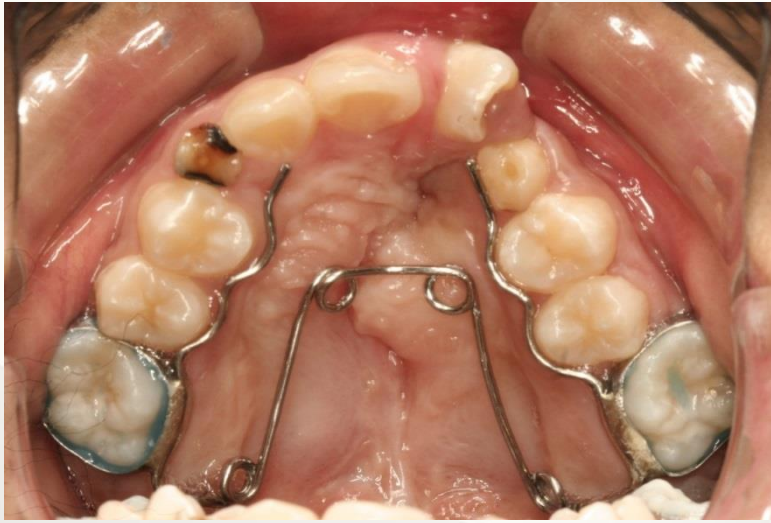
Obturator, CMU NAM I , II , III , Nasal stent



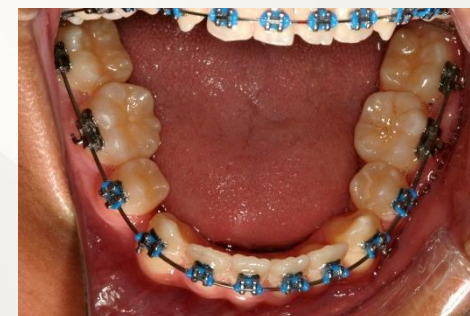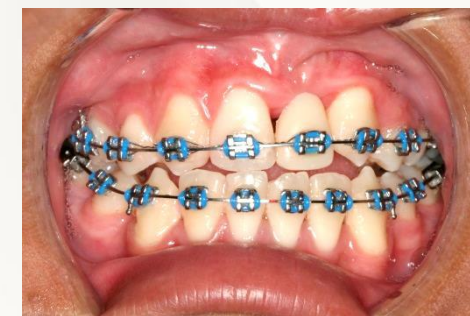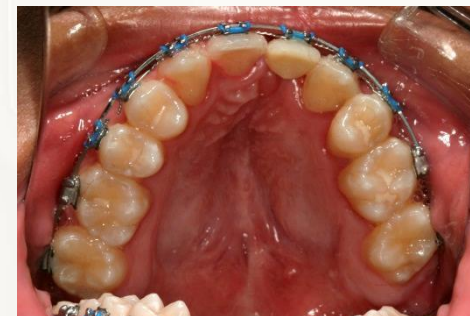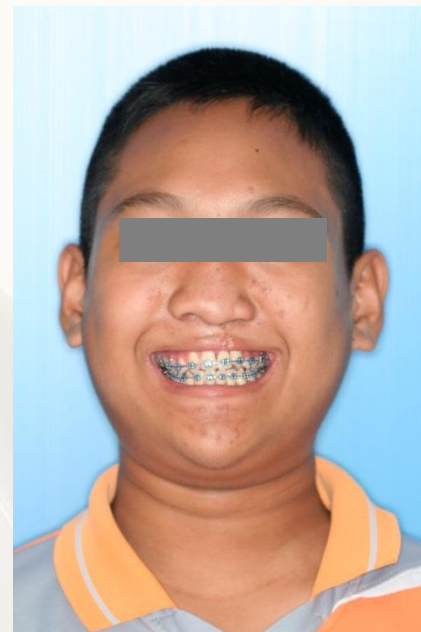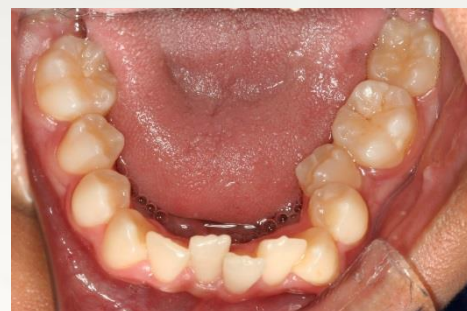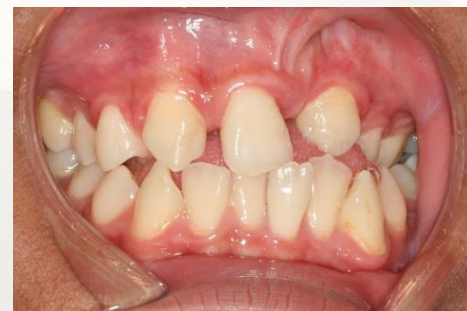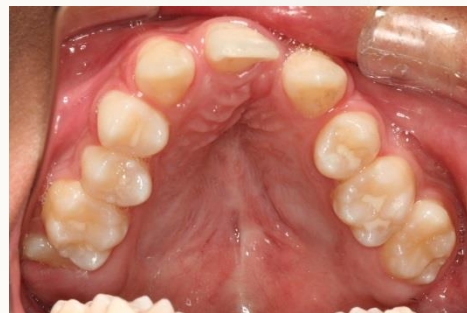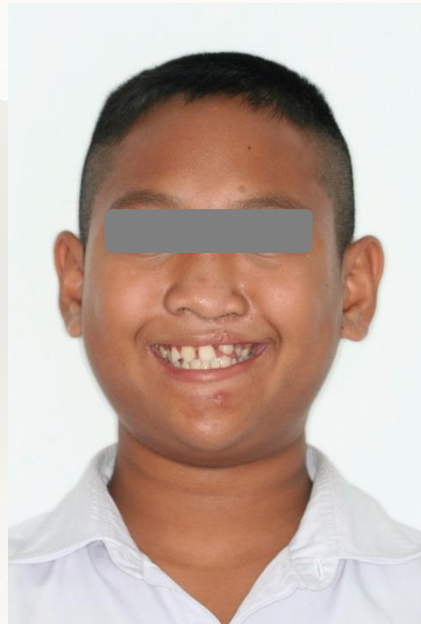Impression & Lab Process



Arch expansion for alveolar bone graft and fixed orthodontic appliance



Fixed orthodontic appliance

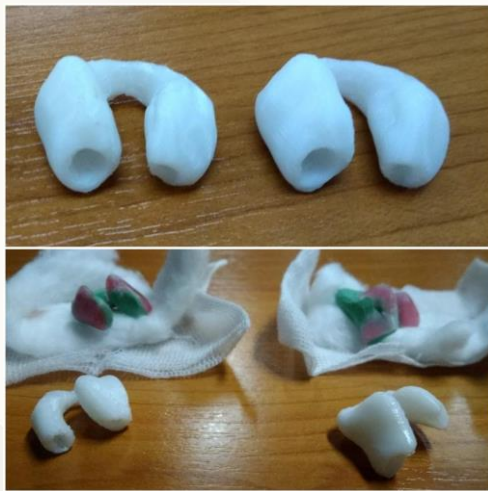
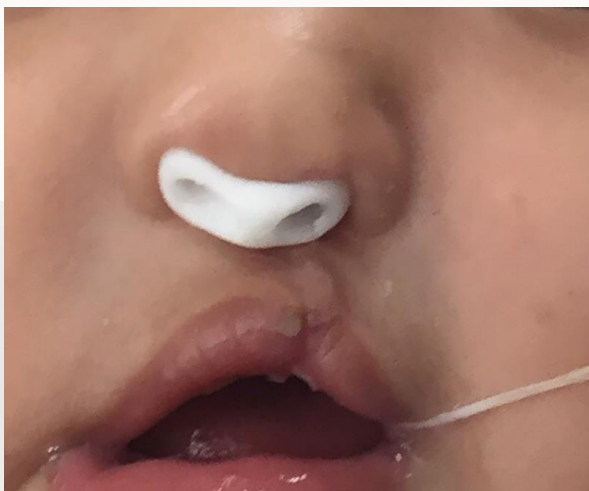
หลังจากอบรม
เป็นอย่างไร

| Age | Orthodontist | Pedodontist | Plastic surgeon/ Maxillofacial surgeon | General dentist | Prosthodontist |
|----------------|---|--|--|--------------------|----------------------------|
| 0-3 mo | - Obturator , NAM - Consult surgeon | Oral hygiene instruction | Counseling For surgery | | |
| 3-6 mo | - Obturator , NAM - Nasal stent (after primary cheiloplasty 24 hrs/day for 6 months, followed by 6-12 hrs/day) | Oral hygiene instruction | Cheiloplasty | | |
| 6 mo - 1 yr | - Obturator - Continued nasal stent | Oral hygiene instruction | | | |
| 1-1.5 yr | | Dental care | Palatoplasty | | |
| 1.5 – 7 yr | Observed growth and occlusion | - Dental care - Observed dental development | | | |
| 7-9 yr | Interceptive Treatment for alveolar bone graft (arch expansion) | Dental care | | Dental care | |
| 9-12 yr | - Interceptive Treatment for crossbite correction or growth modification - Nasal stent (after 2 nd cheiloplasty 24 hrs/day for 12 months , followed by 6-12 hrs/day) | Dental care | Alveolar bone grafting ± 2 nd lip and nose revision | Dental care | |
| 12-18 yr | Orthodontic treatment | | | Dental care | Prosthodontic Treatment |
| > 18 yr | Orthodontic treatment for orthognathic surgery | | Orthognathic surgery | Dental care | (when indicated) |

โอกาสพัฒนา

1. นำ “CMU-DONE พอดี” มาปรับใช้ในอนาคต



2. การสนับสนุนให้ข้อเสนอแนะ
เพื่อสร้างเครือข่ายทีมที่เข้มแข็งจากทีมศูนย์ cleft center



About Us



ทพญ. อรุณี ศิริพานิชกร



ทพญ. ปิยวัลย์ หอภัทรพุดิ

E-mail Sarabudent@gmail.com